

Research Article

Impact of Periodontal Pocket Depth on the Efficiency of Surgical Treatment of Generalized Periodontitis

Mariana Ilkiv, Mykola Rozhko, Vitalii Hereliuk*

Abstract

The paper is aimed at increasing the efficiency of surgical treatment by using a combination of platelet-rich fibrin, a synthetic hydroxyapatite Kergap, minimizing the body's response to operative wound, and improving diagnostic and therapeutic approaches in surgical treatment of stage II-III generalized periodontitis.

The objective of the research was to study the efficiency of using the combination of platelet-rich fibrin, synthetic hydroxyapatite Kergap, magnesium preparation in comprehensive treatment of stage II-III generalized periodontitis at various stages and in different depths of the periodontal pockets.

Materials and Methods. The efficiency of surgical treatment was evaluated using clinical (periodontal pocket depth, attachment level, gingival bleeding, tooth mobility) and laboratory methods (X-ray, computed tomography) 3, 6, and 12 months after surgical treatment.

Results. The clinical picture was characterized by positive changes in all clinical indicators 3, 6 and 12 months after treatment. The best results by clinical and laboratory findings were obtained in case of an average pocket depth of 5-7 mm.

Conclusions. There was demonstrated a high clinical efficiency of using the combination of platelet-rich fibrin, synthetic hydroxyapatite Kergap and magnesium preparation in comprehensive treatment of stage II-III generalized periodontitis.

Keywords

generalized periodontitis; platelet-rich fibrin; hydroxyapatite kergap

Ivano-Frankivsk National Medical University, Ukraine

*Corresponding author: gerelyk@gmail.com



Copyright ©Mariana Ilkiv, Mykola Rozhko, Vitalii Hereliuk, 2020

Problem statement and analysis of the latest research

Periodontal diseases are one of the most common human diseases. Both diagnosis and treatment of generalized periodontitis (GP), especially stage II-III GP, remain challenging and require further improvement. In addition, affected periodontal tissues negatively impact the human body and may contribute to developing systemic complications. Therefore, rational treatment of periodontal diseases, especially stage II-III GP, is relevant being of practical and theoretical significance [1]. The study of the periodontal pockets is an important

component of GP clinical picture. Clinical evaluation usually involves the following characteristics of the periodontal pockets – depth, localization, shape, and location. In most cases, treatment algorithm is based on diagnosing pocket depth, localization, and structure. However, comprehensive periodontal treatment seldom completely considers this important component of diagnosis and clinical characteristics that can negatively impact the efficiency of therapeutic measures and the objectiveness of evaluating the results. Thus, studying the efficiency of differentiated approach to GP treatment through studying the relationship between the

periodontal pocket state at various stages of comprehensive treatment is relevant and requires further study [1, 2]. Alongside with using update methods of operative technique in surgical treatment, the problem of selecting the osteoplastic material is relevant, both formerly and now, as osteoplasty is known to offer great opportunities for rehabilitation of patients [3, 4]. All the existing materials are currently divided into several groups depending on their origin, namely autogenous, allogeneic, xenogeneic, alloplastic, and synthetic [5, 6]. The study of the effect of platelet-rich fibrin (PRF) on periodontal tissues, clinical course of GP and the efficiency of its using for achieving a long-term positive effect in surgical treatment of periodontitis and bone tissue regeneration is relevant. Fibrin is a protein derived from plasma fibrinogen promoting cell mobility in the wound. The role of fibrin is the promotion of cell migration, as well as the capture of platelets and local trapping of growth factors [7, 8]. It creates a combined stimulating effect on both hard and soft periodontal tissue cells. Adhesive properties of PRF improve hemostasis and adaptation of the muco-osseous flap. The use of PRF in surgical treatment of periodontitis, considering healing rate, anti-inflammatory effect, tooth mobility reduction and bone tissue regeneration, is relevant being of research and practical interest [9, 10].

The objective of the research was to study the efficiency of using a combination of PRF, a synthetic hydroxyapatite Kergap, magnesium preparation in comprehensive treatment of stage II-III GP at various stages and in different depths of the periodontal pockets.

1. Materials and Methods

The study included 38 patients with stage II-III chronic GP requiring surgical treatment. For differential study of the relationship between the state of the periodontal pockets and the clinical course of periodontitis in the patients of both groups (Group A – the proposed treatment algorithm; Group B – the control group with traditional treatment), according to the treatment algorithm planned, there was carried out a detailed study of the periodontal pocket

state in all the teeth on the vestibular, lingual, contact (proximal, distal) surfaces which were divided into 4 subgroups depending on their depth (up to 3.5 mm, 3.5-5 mm, 5-7 mm, > 7 mm). As a result, 8 subgroups including 4 subgroups of Group A (A1 – 440 pockets, A2 – 880 pockets, A3 – 660 pockets, A4 – 220 pockets) and 4 subgroups of Group B (B1 – 180 pockets, B2 – 360 pockets, B3 – 270 pockets, B4 – 90 pockets) were formed. The pocket depth was assessed by means of a periodontal probe and studying the indicators of attachment level and the immersion depth of the probe. Cone beam computed tomography was used to assess the presence of the bone pockets. There were selected the following observation periods: before treatment, 3, 6 and 12 months after surgical treatment. The state of periodontal tissues was evaluated using clinical indices, namely the level of attachment, the depth of the periodontal pockets (by the immersion depth of the probe), the degree of bleeding, the indicators of mobility (the periostometry method) and X-ray results. Tooth mobility was measured by the periostometry method by means of an electrical measuring instrument – the Periotest-M (Fig. 1). Standard examination scheme was used. The program of the device provides for automatic hitting the vestibular surface of the tooth with a small tapping head (at a rate of 4 beats per second).

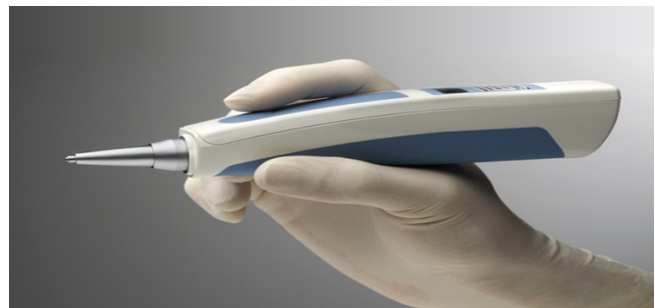


Figure 1. Tooth mobility determination using the periostometry method - the Periotest-M.

Once the button is pushed, the tapping head starts hitting the tooth examined at intervals of 250 microseconds. An impulse is transmitted to periodontal tissues and is reflected from them. The higher periodontal fiber elasticity, the higher the damping characteristics of the periodontal attach-

ment apparatus, and the less duration of tapping head contact with the tooth surface is. The Periotest's scale includes 58 values ranging from -8 to +50.

All the patients examined received standard therapy for GP. The oral cavity and periodontal pockets were irrigated with antiseptic preparations from 2 to 4 times a day. In addition, local treatment included topical application of dental gel Metrogyl Denta (Unique Pharmaceutical Laboratories, India; Registration No UA/2871/01/01 of March 20, 2015) with a stable 0.25% chlorhexidine concentration and 10% metronidazole concentration. Local treatment was completed with the application of the Solcoseryl Dental Adhesive Paste (ICN Switzerland AG, Switzerland; Registration No.UA/13026/01/01 of July 12, 2013.) Multivitamins were prescribed. All the patients received 1 tablet of the complete multivitamin complex Duovit (KRKA d.d., Novo Mesto, Slovenia) after meal for 1 month; in addition, magnesium preparations were prescribed, the patients of Group A received 1 tablet of Magnicum (Public Joint-Stock Company, Kyiv Vitamin Factory, Ukraine) twice a day.

Furthermore, at the initial stage of treatment, all the patients were taught on proper oral hygiene care and individual oral hygiene means were selected. All the patients underwent traditional flap surgery using a combination of PRF and synthetic hydroxyapatite Kergap. Once anaesthesia was conducted, and the muco-osseous flaps were formed with the maintenance of all the principles of maximum blood supply preservation, the infected granulation tissue and subgingival calculus deposits were removed. Sutures were used to secure the muco-osseous flaps back in place. All the patients were examined on the 2nd-3rd, 7th-8th days after surgery to control wound healing process (registration of postoperative complications in case of their presence, divergence of wound margins, severity of pain syndrome, inflammatory response, signs of wound infection) and treat the wound surface with drugs. The sutures were removed on the 8th-10th days depending on individual clinical case.

Statistical analysis was performed using the standard software package Statistica for Windows

12.0 (StatSoft, Tulsa, OK, USA). To create a database, there was used MS Office Excel 2007.

2. Results and Discussion

The depth of the periodontal pockets reduced in almost all subgroups 3 and 6 months after surgical treatment. In 12 months, a statistically insignificant depth increase was observed in separate groups that might be partially associated with poor oral hygiene. In subgroups A1 and B1, there was no statistically significant difference in the pocket depth. In subgroup A2, there was observed a statistically significant difference as compared to the control group, that indicated the advantages of the proposed treatment plan, including its pharmacological component. The most convincing results were obtained in subgroups A3 and B3, where surgery was used. After surgical treatment, the depth of the periodontal pockets in subgroup A3 was significantly lower that substantiated the efficiency of the proposed treatment plan (Table 1).

When studying the level of attachment, significantly less attachment loss was observed in subgroups with the proposed treatment algorithm, especially subgroups 3 and 4, that might indicate a shift in the level of attachment in the coronal direction under the influence of surgical treatment (Table 2).

The indicators of gingival bleeding reduced in all the subgroups; however, in subgroups A1, B1 and A3, B3, they were the closest to normal limits. In general, the results of subgroups B were lower as compared to those of subgroups A within the same observation periods. There was a statistically significant difference between the main and control groups in subgroups A2, B2, A3, B3 and A4, B4 that confirmed the advantages of the proposed treatment plan. Due to the quality of the initial stage of treatment, there was no statistically significant difference in bleeding indicators between subgroup A1 and subgroup B1 (Table 3).

Special attention was paid to the study of tooth mobility as the main criterion for anatomic and physiological periodontal repair. The X-ray picture of the bone in a certain area, the height of the interdental septum, the state of the bone pocket are,

Table 1. Indicators of periodontal pocket depth (mm) in patients with stage II-III GP under the influence of treatment ($M \pm m$).

Observation period	Groups of periodontal pockets							
	A1	B1	A2	B2	A3	B3	A4	B4
Before treatment	3.28 ± 0.11	3.31 ± 0.12	4.42 ± 0.11	4.56 ± 0.11	6.13 ± 0.14	6.27 ± 0.12	7.11 ± 0.09	7.23 ± 0.08
3 months after treatment	1.64 $\pm 0.13!$	1.89 $\pm 0.11!$	2.32 $\pm 0.09!*$	2.78 $\pm 0.11!$	1.59 $\pm 0.12!*$	3.05 $\pm 0.14!$	2.23 $\pm 0.08!*$	3.34 $\pm 0.12!$
6 months after treatment	1.78 $\pm 0.14!$	1.95 $\pm 0.11!$	2.22 $\pm 0.12!*$	2.89 $\pm 0.09!$	2.09 $\pm 0.11!*$	3.11 $\pm 0.15!$	2.54 $\pm 0.07!*$	3.16 $\pm 0.11!$
12 months after treatment	2.25 $\pm 0.11!$	2.38 $\pm 0.13!$	2.49 $\pm 0.09!*$	3.16 $\pm 0.12!$	2.14 $\pm 0.12!*$	3.19 $\pm 0.16!$	2.82 $\pm 0.11!*$	3.29 $\pm 0.14!$

Notes:

* - a statistically significant difference as compared to Group B ($p < 0.05$);

! - a statistically significant difference as compared to the indicators before treatment ($p < 0.05$).

Table 2. Indicators of periodontal attachment (mm) in patients with stage II-III GP under the influence of treatment ($M \pm m$).

Observation period	Groups of periodontal pockets							
	A1	B1	A2	B2	A3	B3	A4	B4
Before treatment	2.28 ± 0.11	2.31 ± 0.12	3.42 ± 0.11	3.56 ± 0.11	7.13 ± 0.14	7.27 ± 0.12	8.11 ± 0.09	8.23 ± 0.08
3 months after treatment	1.85 $\pm 0.13!$	1.91 $\pm 0.15!$	2.02 $\pm 0.09!*$	2.83 $\pm 0.11!$	5.45 $\pm 0.12!*$	6.23 $\pm 0.14!$	7.23 $\pm 0.08!$	7.34 $\pm 0.12!$
6 months after treatment	1.79 $\pm 0.13!$	1.88 $\pm 0.15!$	2.17 $\pm 0.12!*$	2.76 $\pm 0.11!$	5.09 $\pm 0.11!*$	6.11 $\pm 0.15!$	6.54 $\pm 0.07!*$	7.16 $\pm 0.11!$
12 months after treatment	2.07 ± 0.14	2.18 ± 0.13	2.19 $\pm 0.09!*$	3.04 $\pm 0.13!$	5.27 $\pm 0.12!*$	6.19 $\pm 0.16!$	6.82 $\pm 0.11!*$	7.49 $\pm 0.14!$

Notes:

* - a statistically significant difference as compared to Group B ($p < 0.05$);

! - a statistically significant difference as compared to the indicators before treatment ($p < 0.05$).

undoubtedly, important characteristics of the periodontium; however, tooth mobility is the marker that unites and represents laboratory findings. It is the normalization of tooth mobility that may indicate the elimination of the inflammatory process,

the restoration of blood supply, metabolic processes, functional load on periodontal tissues. Currently, due to periostometry, we have new opportunities for evaluating this indicator both in norm and in case of pathological changes in the periodontium.

Table 3. Indicators of gingival bleeding (points) in patients with stage II-III GP under the influence of treatment ($M \pm m$).

Observation period	Groups of periodontal pockets							
	A1	B1	A2	B2	A3	B3	A4	B4
Before treatment	1.36 ± 0.07	1.44 ± 0.09	1.79 ± 0.12	1.82 ± 0.11	2.25 ± 0.13	2.36 ± 0.12	2.59 ± 0.13	2.42 ± 0.14
3 months after treatment	0.23 ± 0.03!	0.17 ± 0.05!	0.37 ± 0.08!*	0.68 ± 0.09!	0.22 ± 0.06!*	0.41 ± 0.08!	0.29 ± 0.05!	0.42 ± 0.07!
6 months after treatment	0.16 ± 0.09!	0.25 ± 0.05!	0.33 ± 0.07!*	0.52 ± 0.05!	0.27 ± 0.07!*	0.45 ± 0.08!	0.37 ± 0.09!*	0.56 ± 0.12!
12 months after treatment	0.27 ± 0.08!	0.39 ± 0.09!	0.48 ± 0.05!*	0.54 ± 0.09!	0.35 ± 0.06!*	0.63 ± 0.05!	0.42 ± 0.09!*	0.61 ± 0.11!

Notes:

* - a statistically significant difference as compared to Group B ($p < 0.05$);

! - a statistically significant difference as compared to the indicators before treatment ($p < 0.05$).

The study of diagnostic value of tooth mobility in surgical treatment of stage II-III GP is of special interest (Table 4).

Before treatment, there were observed no statistically significant differences in tooth mobility among the patients with stage II-III GP. In subgroups A1 and B1, a slight decrease in mobility indicators 3 and 6 months after treatment was observed; however, there was no statistically significant difference between subgroups. Clinical indicators of tooth mobility obtained 3 months after surgery were lower in almost all subgroups of the maxillary and mandibular teeth as compared to those in Group B; however, a statistically significant difference was found in the mandibular incisors and molars, and the maxillary premolars. Clinical indicators of tooth mobility obtained 6 and 12 months after surgery were lower in almost all subgroups of the maxillary and mandibular teeth as compared to those in Group B as well. There was found a statistically significant difference between subgroups that confirmed higher efficiency of the proposed treatment algorithm.

3. Conclusions

To increase the efficiency of diagnosis, treatment planning and surgery, we have proposed the algorithm for differential assessment of periodontal pocket state that allowed us to monitor disease and treatment dynamics more objectively.

The highest efficiency of surgical treatment was observed in case of an average pocket depth of 5-7 mm.

The use of the combination of PRF and hydroxyapatite Kergap has proven to be highly effective in surgical treatment of patients with GP demonstrating the short and long-term success.

4. Prospects of Further Researches

The algorithm proposed can be used in surgical treatment of patients with stage II-III GP. The proposed method of assessing the periodontal state by a differential study of pocket state can be interesting for scientific research.

Conflict of Interest

The authors stated no conflict of interest.

Table 4. Tooth mobility (points) in patients with stage II-III GP under the influence of treatment (M±m).

Observation period	Groups of periodontal pockets							
	A1	B1	A2	B2	A3	B3	A4	B4
Before treatment	+2.53 ± 0.17	+2.79 ± 0.21	+7.34 ± 0.15	+7.65 ± 0.18	+22.56 ± 0.33	+22.12 ± 0.21	+23.22 ± 0.25	+23.12 ± 0.21
3 months after treatment	+1.72 ± 0.09!	+2.08 ± 0.13!	+2.12 ± 0.11!*	+3.88 ± 0.09!	+10.09 ± 0.11!*	+15.11 ± 0.25!	+12.09 ± 0.13!*	+17.11 ± 0.45
6 months after treatment	+1.98 ± 0.11!	+2.03 ± 0.13!	+2.25 ± 0.08!*	+3.43 ± 0.19!	+8.50 ± 0.12!*	+12.50 ± 0.16!	+11.90 ± 0.17!*	+15.90 ± 0.11!
12 months after treatment	+2.31 ± 0.15	+2.23 ± 0.13	+3.27 ± 0.19!	+3.56 ± 0.13!	+9.22 ± 0.13!*	+13.37 ± 0.16!	+12.50 ± 0.13!*	+16.50 ± 0.12!

Notes:

* - a statistically significant difference as compared to Group B (p<0.05);

! - a statistically significant difference as compared to the indicators before treatment (p<0.05).

Financial Disclosure

The authors declared no financial support.

References

- [1] Danylevskiy NF, Borysenko AV. Zabolevaniya parodonta. Kyiv: Zdorovia; c2000. 292p.
- [2] Pavlenko OV, Bida RYu. Plasma enriched with platelets: from fundamental science to clinical practice. Bulletin of Problems in Biology and Medicine. 2016; 1 (2): 241-244. [published in Ukrainian]
- [3] Timofeev AA. Rukovodstvo po chelyustno-litseyoy khirurgiyi i khirurgicheskoy stomatologiyi. Kyiv: Ruta Turs; c2002. 1024p.
- [4] Kirichenko VN, Bezrukov SG, Marchenko NV. Vliyaniye osteoplasticheskikh materialov na techeniye vosstanovitelnykh protsessov v otdalennyye sroki posle khirurgicheskogo lecheniya parodontita. KTZh. 2013; 1: 46-49.
- [5] Shvets AI. Anteprosthetic osteoplastic correction of orthopedic bed of jaws with application of bioceramics "KERGAP" and "MAGNI-COLIN". Innovation in Stomatology. 2014; 3: 56-59. [published in Ukrainian]
- [6] Panda S, Ramamorthi S, Jayakumar ND et al. Platelet rich fibrin and alloplast in the treatment of intrabony defect. J Pharm Bioallied Sci. 2014; 6 (2): 127-131. DOI: <https://doi.org/10.4103/0975-7406.129178> [PMid:24741282 PM-Cid:PMC3983743]
- [7] Maney P, Amornponcharoen M, Palaiologou A. Applications of Plasma Rich in Growth Factors (PRGF) in Dental Surgery: A Review. J West Soc Periodontol Periodontal Abstr. 2013; 61 (4): 99-104.
- [8] Kumar A, Lal N, Singhal R. Comparative Evaluation of Periosteum as a Barrier Membrane with and Without an Alloplastic Bone Graft in Periodontal Osseous Defects: A 9 Months Follow-Up Study. J Indian Soc Periodontol. 2014; 18 (4): 493-496. DOI: <https://doi.org/10.4103/0972-124X.138706> [PMid:25210266 PM-Cid:PMC4158593]

- [9] Plaviuk LYu, Hereliuk VI. Dynamika okremykh pokaznykiv zapalnoho protsesu u khvorykh na heneralizovanyi parodontyt I-II stupenia rozvytku na tli korektsii preparatamy mahniiu. Galician Medical Journal. 2011; 2: 90-95.
- [10] Staudte H, Kranz S, Völpel A et al. Comparison of Nutrient Intake Between Patients With Periodontitis and Healthy Subjects. Quintessence Int 2012; 43: 907-916.

Received: 2020-07-03

Revised: 2020-08-05

Accepted: 2020-08-15